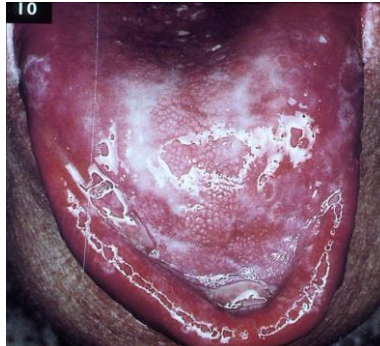
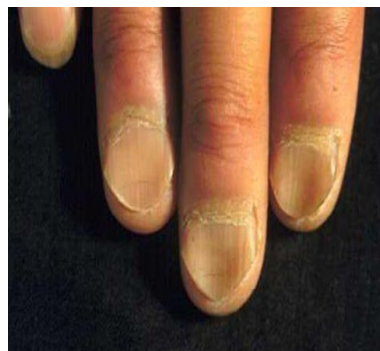

Model for OSPE Exam I- 2019

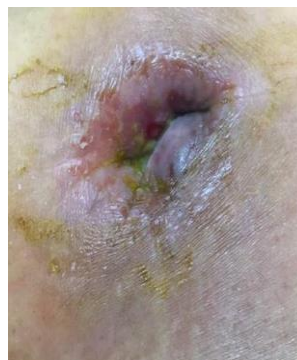1- In a patient with iron deficiency anemia this tongue was seen, what is best description for this tongue?



2- In a patient with pallor this nail abnormality was detected, what is it? Describe it? Give one cause.



3- This discharge was seen coming from the umbilicus, what is the discharge? give one cause.



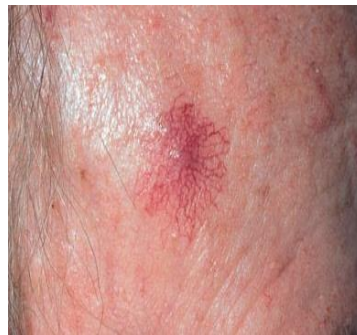4- Which of the followings is not an indication for liver biopsy:

- 1- Assess unexplained abnormal liver biochemistry
- 2- Diagnosis of the type of cirrhosis
- 3- Evaluation of undetermined liver masses and cysts
- 4- Diagnosis of acute viral hepatitis

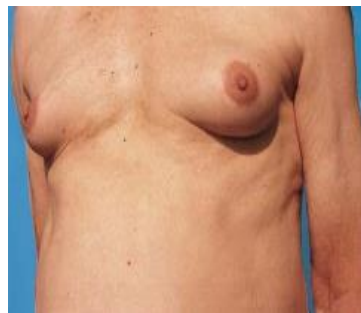5- Which of the followings is not a complication of GIT endoscopy:

- 1- Bowel perforation
- 2- Bleeding
- 3- Cholangitis
- 4- Hepatitis

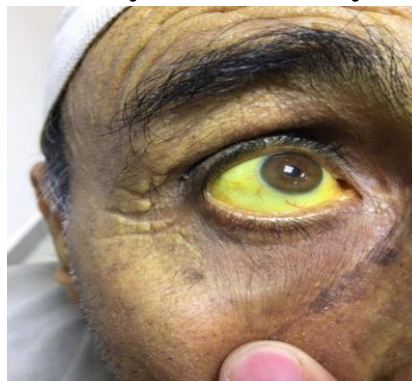6- A 62 years old male with cirrhosis had this lesion on his chest wall, what is the lesion? Enumerate three differential diagnoses.



7- This breast abnormality was seen in a patient with liver cell failure. What is it? And give 3 drugs that may cause it.



8- A) What is the abnormality seen in the eye?



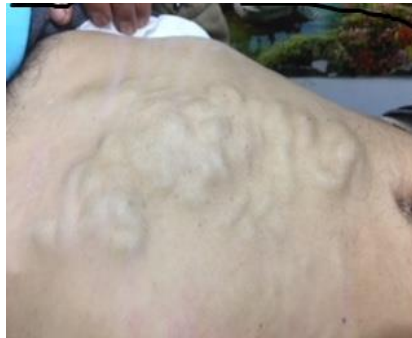B) Give its different clinical types and give one cause for each:

1-e.g.

2-e.g.

3-e.g.

9- A) What is the vascular abnormality seen above the umbilicus in this cirrhotic patient ?



B) In patients with liver cirrhosis it is a sure sign of?

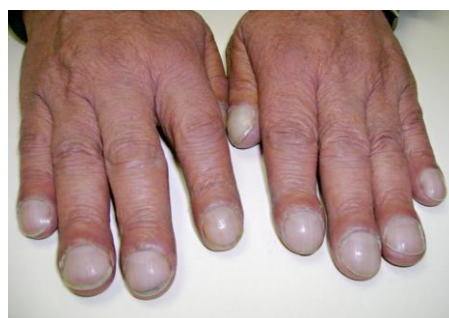C) The direction of filling is:

1- Away from umbilicus

2- Toward the umbilicus

3- From upward to downward

10- A) What is the finger nail abnormality seen?



B) Give 3 GIT causes of this abnormality

1-

2-

3-